

Radially expanding laparoscopic trocar ports significantly reduce postoperative pain in all age groups

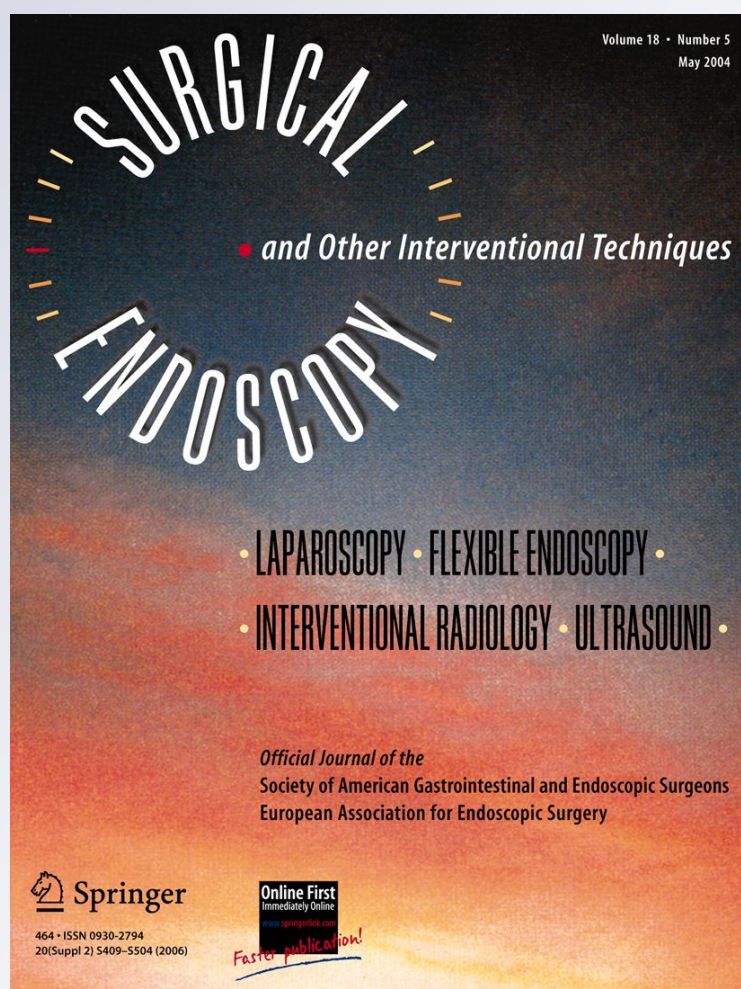
**Simon C. Mordecai, Oliver
W. N. Warren & Stephen J. Warren**

Surgical Endoscopy

And Other Interventional Techniques
Official Journal of the Society of
American Gastrointestinal and
Endoscopic Surgeons (SAGES) and
European Association for Endoscopic
Surgery (EAES)

ISSN 0930-2794

Surg Endosc
DOI 10.1007/s00464-011-1963-z



Your article is protected by copyright and all rights are held exclusively by Springer Science+Business Media, LLC. This e-offprint is for personal use only and shall not be self-archived in electronic repositories. If you wish to self-archive your work, please use the accepted author's version for posting to your own website or your institution's repository. You may further deposit the accepted author's version on a funder's repository at a funder's request, provided it is not made publicly available until 12 months after publication.

Radially expanding laparoscopic trocar ports significantly reduce postoperative pain in all age groups

Simon C. Mordecai · Oliver W. N. Warren ·
Stephen J. Warren

Received: 7 May 2011 / Accepted: 25 August 2011
© Springer Science+Business Media, LLC 2011

Abstract

Background Trocar entry points have been identified as a significant source of pain after laparoscopic surgery. This is particularly true of the larger 12-mm ports that require deep fascial closure to avoid port-site herniation. We investigated whether using radially expanding trocars not requiring fascial closure compared to conventional cutting trocars for the 12-mm port in transabdominal preperitoneal (TAPP) hernia repairs had any effect on postoperative analgesic requirements and return to work or normal activity.

Methods The number of days analgesia was required postoperatively and the number of days taken to return to normal activity was recorded for 143 consecutive patients who underwent TAPP hernia repair by a single experienced laparoscopic surgeon. Exactly the same operative technique was used in these patients with the exception of the 12-mm port site entry. In group 1 (104 patients), a conventional cutting trocar was used requiring deep fascial closure. In group 2 (39 patients), a radially expanding trocar was used and the fascial defect was not closed.

Results Analgesia was required for an average of 10.5 days in group 1 and 2.4 days in group 2 ($P < 0.001$). The average time to return to work or to normal activity was 23.4 days in group 1 and 15.6 days in group 2 ($P = 0.004$). There was no significant difference between the two groups with respect to the patients' age, sex, or operating time.

Conclusion Using the laparoscopic TAPP hernia repair as a standardised operation, changing from 12-mm fascial port closure to a technique that uses port dilation (not requiring a potentially "tight" deeper fascial closure) in a similar group of patients shows that there is a significant reduction in postoperative analgesic requirement and an earlier return to productive work or normal lifestyle. Perhaps dilating ports should replace those larger 10-, 12-, and 15-mm ports that require deeper sutures in all laparoscopic surgical operations.

Keywords Laparoscopy · Radially expanding · Trocar · Port site · Outcome

The benefits of laparoscopic surgery over more conventional open techniques are well documented. Smaller incisions are associated with fewer postoperative complications, quicker return to normal activity, and shorter hospital stay. For enhanced patient care and experience and economic reasons there is an increasing trend toward day-case surgical procedures, and laparoscopic surgery therefore has an important place in day surgery. However, postoperative pain is the main cause for a delay in discharge after laparoscopic surgery [1, 2] and there is much debate over the best surgical techniques to minimise this.

Trocar entry points have been identified as a significant source of pain after laparoscopic surgery [3], and various trocar designs and port-site closure techniques have been proposed to address this [4, 5]. Conventional cutting trocars are designed to cut through the abdominal wall muscles to place the port in an intraperitoneal position; however, these carry the risk of abdominal wall bleeding, visceral injury, and incisional hernia [6]. The

S. C. Mordecai (✉) · O. W. N. Warren · S. J. Warren
Department of Laparoscopic Surgery, Chase Farm Hospital,
The Ridgeway, Enfield, Middlesex EN2 8JL, UK
e-mail: simon_mordecai@yahoo.com

incidence of incisional hernia after the use of 12-mm cutting trocars has been found to be 8% without fascial closure and 0.22% with fascial closure [7]. Thus, modern guidelines recommend fascial closure of trocar sites of 10 mm or larger. While closing fascial defects significantly reduces the incidence of postoperative incisional hernia, adequate closure of the fascia can be very difficult, particularly in obese patients, and there is the risk of injury to underlying bowel or omentum.

Radially expanding access devices have been introduced to address these complications associated with cutting trocars. They work by splitting the muscle fascia along its fibres; this is less traumatic than cutting trocars resulting in lower rates of bleeding and less postoperative pain. In addition, because the wound is created by stretching the fibres as opposed to cutting them, the fascia tends to recoil back on itself after the port is removed and the actual remaining defect is half that of a comparable-sized cutting trocar [8]. Therefore, there is no need to routinely close the fascia defects made by radially expanding trocars thus avoiding the risk of stitching underlying bowel or omentum [9].

Despite the documented advantages of radially expanding trocars over cutting trocars, the analgesic benefit postoperatively, which is the main factor that determines hospital discharge, remains inconclusive [10–12]. The current study aims to address this issue by specifically looking at postoperative analgesic requirements and return to normal activity in patients who underwent a standardised operation. All patients underwent laparoscopic transabdominal preperitoneal (TAPP) inguinal hernia repair with the use of either a conventional cutting trocar or radially expanding access. We hypothesise that the patient group subjected to the radially expanding trocar will have less postoperative pain and return to normal activity sooner than those subject to the cutting trocar.

Materials and methods

This was retrospective study of 143 consecutive patients who had laparoscopic TAPP hernia repair (from 2004 to 2010) performed by a single experienced laparoscopic surgeon using exactly the same surgical technique with the exception of the 12-mm port access. In group 1 (104 patients), a conventional cutting trocar (Versaport™ Plus V2, Covidien, Mansfield, MA) was used for the 12-mm port and at the end of the operation the fascia was closed using a No. 1 coated Vicryl J-needle (Ethicon, Somerville, NJ). In group 2 (39 patients), the VersaStep™ Plus (Covidien) radially expanding bladeless trocar was used for the 12-mm port and the fascial defect did not need to be closed. For the two remaining 5-mm ports, identical trocars

were used in both groups (Fig. 1), and the 5-mm resultant defects did not require fascial closure. The skin at all port sites was closed using a 3/0 undyed Vicryl subcuticular suture for both groups. All patients received similar general anaesthesia, and the same local anaesthetic (10 ml of 0.5% bupivacaine) was applied to the 12-mm port site after skin closure.

Patients were discharged from hospital once their observations were stable and their pain could be managed with oral analgesia, but all within 24 h. They were each given diclofenac and co-codamol to take regularly post-operatively for as long as required. At their 4-week post-operative outpatient check, the day they stopped requiring the analgesia and the time taken to return to work or normal activity were noted. Patients with chronic diseases requiring regular analgesia or those who did not record their analgesic requirements were excluded.

The results were analysed using the independent samples *t*-test to establish a significant difference between the mean analgesic requirement and return to normal activity between the two groups. Values of $P < 0.05$ were considered significant.

Results

Table 1 shows the demographics for each group and that there is no significant difference in age, male-to-female ratio, and operating time between the groups. Table 2 shows and Fig. 2 illustrates the average analgesic requirement (in days) and the average return to work/normal activity for each of the subject groups.

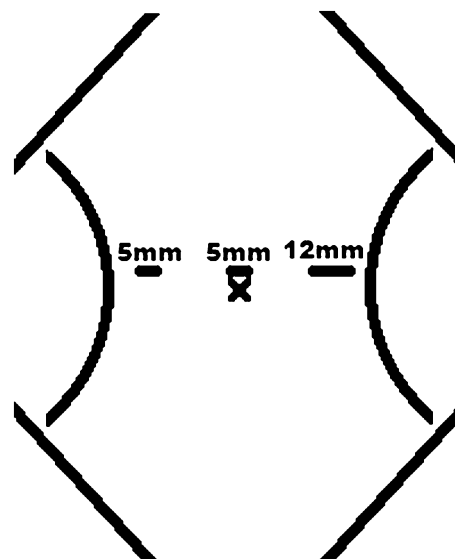


Fig. 1 Schematic diagram of the laparoscopic ports used for the TAPP hernia repairs. Only the 12-mm port is different in each group

Table 1 Demographics of each group

	Cutting trocar group	Radially expanding trocar group	<i>P</i>
Sample size	104	39	
Mean age	57.8	56.4	0.645
Percentage male (%)	94.2	97.4	
Percentage bilateral repair (%)	45.2	38.5	
Mean operating time, unilateral (min)	30.8	32.6	0.782
Mean operating time, bilateral (min)	39.9	44.2	0.365

Table 2 Average analgesic requirement and return to work/normal activity

	Cutting trocar	Radially expanding trocar	<i>P</i>
Average analgesic requirement	10.5	2.4	<0.001
Average return to work/normal activity	23.4	15.6	0.004

Discussion

This study showed that radially expanding trocars significantly reduce postoperative analgesic requirement ($P < 0.001$) and time to return to normal activity ($P = 0.004$) when compared with conventional cutting trocars for patients who underwent laparoscopic TAPP hernia repair as a standardised operation. Apart from changing the 12-mm port access, all other variables were kept constant in the two groups. There was no statistical difference in patients' age or operating time, and the surgeon, surgical technique, and postoperative treatment were the same for each group.

Although current literature suggests that radially expanding trocars are advantageous in that they are less traumatic, have lower bleeding rates, and have smaller defects which need not be closed, still some argument exists over analgesic benefit.

Bhojru et al. [11] conducted a randomised clinical trial on 250 adults who underwent elective laparoscopic procedures and were randomly assigned to either conventional cutting trocars or radially expanding trocars. They found significantly fewer postoperative complications in the radially expanding trocar group and generally lower pain scores, although the difference was not significant. In that study, however, 16 different surgeons performed the procedures and the operation itself was not consistent. These variables may well have contributed to the different pain

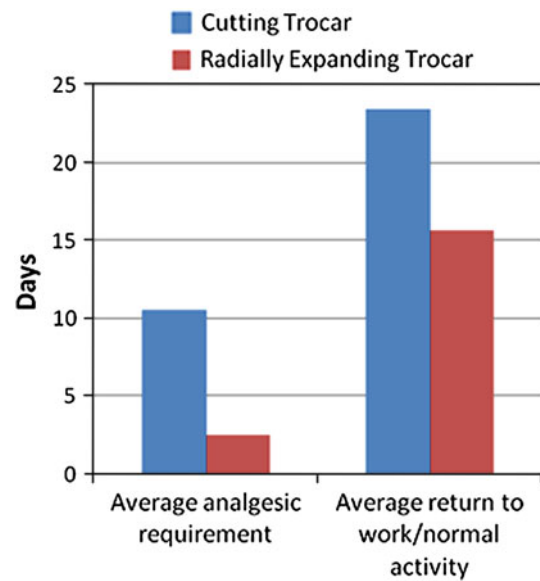


Fig. 2 Average analgesic requirement and return to work/normal activity for each group

scores experienced in each group. Lam et al. [12] did a similar study on 54 patients who underwent laparoscopic cholecystectomy and found that the radially expanding trocar does produce significantly less early postoperative pain. Bisgaard et al. [10], however, carried out a patient- and observer-blinded randomised trial of 80 patients who underwent laparoscopic cholecystectomy using either radially expanding trocars or conventional cutting trocars and found no significant difference in postoperative pain scores. In that study, 23 of the 38 patients in the radially expanding group required additional fascial incision for gallbladder retraction. The proposed analgesic benefit of the radial expanding device is a result of the fact that the muscle fibres are split rather than cut [13]. Therefore, this study cannot truly comment on whether there is an analgesic benefit with the radial expanding trocar as the majority of cases in the radial group had eliminated the benefits of the blunt nontraumatic radial expanding system. In our study, only the trocar itself was passed through the abdominal wall, suggesting that the differences in analgesic requirements between the groups was solely due to the different trocars used and no other traumatic influences.

Tarnay et al. [14] compared entry force between different laparoscopic trocar systems tested on pig abdomens. They found that the force required to push blunt dilators was 25.53 lb compared with just 13.2 lb for cutting trocars. They suggest that the high entry force results in loss of operator control and thereby contributes to an increased risk of vascular and visceral injury. A more recent article [15] contradicts this and states that the radially expanding system requires minimal downward pressure and the blunt tip further reduces the potential for visceral injuries.

Furthermore, the force needed to dilate the mesh trocar feels no different than that required to insert a conventional cutting trocar. Once inserted, the trocar does not slide out easily with instrumentation, further reducing the risk of trocar-related vascular or visceral injury. In our study, there were no major vascular or visceral injuries related to entry force when inserting the radially expanding trocar.

To our knowledge this is the only study that has specifically addressed the postoperative analgesic requirements for two different port-site entry techniques while keeping all other variables the same. We are aware that the study design could have been improved with observer blinding at the 4-week follow-up appointment. However, we do not feel that this would have really affected the results because at the time of follow-up we relied on the patients' own diaries of how long they used the analgesics and when they returned to normal activity. Therefore, in this instance observer bias would have had no influence on the results. We are also aware of the discrepancy in sample size (104 vs. 39) between the two groups. The reason for this is that radially expanding trocars are relatively new and have therefore not been used on as many patients. Despite this, though, we have still been able to minimise type II errors and have found statistically significant results. The radially expanding trocars are now used in all our patients undergoing TAPP hernia repair. This will create a larger sample size for future studies.

In conclusion, using a laparoscopic TAPP hernia repair as a standardised operation, by changing from a 12-mm fascial port closure to a radially expanding trocar (not requiring a potentially "tight" deeper fascial closure) in a similar group of patients, there is a statistically significant reduction in postoperative analgesic requirement and an earlier return to normal lifestyle. Perhaps radially expanding ports should replace the larger 10-, 12-, and 15-mm ports which require deeper sutures in all laparoscopic surgical operations.

Disclosures Simon Mordecai, Oliver Warren, and Stephen Warren have no conflicts of interest or financial ties to disclose.

References

1. Lau H, Brooks DC (2001) Predictive factors for unanticipated admissions after ambulatory laparoscopic cholecystectomy. *Arch Surg* 136:1150–1153
2. Fiorillo MA, Davidson PG, Fiorillo M, D'Anna JA Jr, Sithian N, Silich RJ (1996) 149 Ambulatory laparoscopic cholecystectomies. *Surg Endosc* 10:52–56
3. Bisgaard T, Klarskov B, Rosenberg J, Kehlet H (2001) Characteristics and prediction of early pain after laparoscopic cholecystectomy. *Pain* 90:261–269
4. Vilos GA, Ternamian A, Dempster J, Laberge PY (2007) Laparoscopic entry: a review of techniques, technologies, and complications. *J Obstet Gynaecol Cancer* 29:433–465
5. Durai R, Ng PC (2009) Novel methods of closing 10-mm laparoscopic port-site wounds. *J Laparoendosc Adv Surg Technol A* 19:791–793
6. Leibl BJ, Schmedt CG, Schwarz J, Kraft K, Bittner R (1999) Laparoscopic surgery complications associated with trocar tip design: review of literature and own results. *J Laparoendosc Adv Surg Technol A* 9:135–140
7. Kadar N, Reich H, Liu CY, Manko GF, Gimpelson R (1993) Incisional hernias after major laparoscopic gynecologic procedures. *Am J Obstet Gynecol* 168:1493–1495
8. Bhojrul S, Mori T, Way LW (1996) Radially expanding dilatation. A superior method of laparoscopic trocar access. *Surg Endosc* 10:775–778
9. Turner DJ (1996) A new, radially expanding access system for laparoscopic procedures versus conventional cannulas. *J Am Assoc Gynecol Laparosc* 3:609–615
10. Bisgaard T, Jakobsen HL, Jacobsen B, Olsen SD, Rosenberg J (2007) Randomized clinical trial comparing radially expanding trocars with conventional cutting trocars for the effects on pain after laparoscopic cholecystectomy. *Surg Endosc* 21:2012–2016
11. Bhojrul S, Payne J, Steffes B, Swanstrom L, Way LW (2000) A randomized prospective study of radially expanding trocars in laparoscopic surgery. *J Gastrointest Surg* 4:392–397
12. Lam TY, Lee SW, So HS, Kwok SP (2000) Radially expanding trocar: a less painful alternative for laparoscopic surgery. *J Laparoendosc Adv Surg Technol A* 10:269–273
13. Yim SF, Yuen PM (2001) Randomized double-masked comparison of radially expanding access device and conventional cutting tip trocar in laparoscopy. *Obstet Gynecol* 97:435–438
14. Tarnay CM, Glass KB, Munro MG (1999) Entry force and intra-abdominal pressure associated with six laparoscopic trocar-cannula systems: a randomized comparison. *Obstet Gynecol* 94:83–88
15. Shekarriz B, Gholami SS, Rudnick DM, Duh QY, Stoller ML (2001) Radially expanding laparoscopic access for renal/adrenal surgery. *Urology* 58:683–687